150 Mohs Micrographic Surgery

Charlene Lam and Allison T. Vidimos

Chapter Contents

Introduction . . . 2582
History . . . 2583
Training in Mohs Micrographic Surgery . . . 2584
Appropriate Use Criteria and Cost-Effective Care . . . 2584
Indications . . . 2584
Contraindications . . . 2589
Preoperative History and Considerations . . . 2589
Technique . . . 2589
Variations/Refinements . . . 2589
Challenges and Pitfalls . . . 2590
Reconstruction . . . 2593
Postoperative Care . . . 2593
Complications . . . 2593
Future Trends . . . 2593

Synonyms: ■ Mohs surgery ■ Chemosurgery ■ Mohs chemosurgery (fresh tissue technique and fixed tissue technique)

Key features

- Based upon the concept of contiguous spread of a tumor from a single focus
- 100% microscopic tissue margin examination
- Highest evidence-based cure rate for cutaneous malignancies, but success is dependent on resources and skills of the surgeon and histotechnician
- Same physician serves as both surgeon and pathologist
- Precise excision of cancerous tissue
- Preservation of the maximum amount of non-cancerous tissue
- Total tissue control and precise mapping
- Immediate re-excision of residual cancerous tissue as indicated
- Reconstruction typically performed by Mohs surgeon
- Exceedingly low complication rate

INTRODUCTION

Mohs micrographic surgery (MMS) is a specialized method for skin cancer removal that combines surgery with pathology resulting in an excellent cure rate. The goals are to remove only the cancerous tissue while viewing the complete margin, thereby preserving the maximum amount of normal tissue (i.e. tissue-sparing). From a functional, aesthetic and reconstructive perspective, tissue-sparing is especially important for skin cancers in the periorbital, nasal, auricular, perioral, digital, and anogenital areas. MMS is also the preferred treatment method for skin cancers that are clinically poorly defined, recurrent, and/or have a higher risk of recurrence because of histologic features or anatomic location (Table 150.1).

There are four major components: surgical excision, histopathologic examination, precise mapping, and wound management. The *surgical* component consists of removing a disc of tissue with a beveled surgical margin (Fig. 150.1A). The disc of tissue, or "layer", ensures that the entire 360° of tumor margin is circumferentially removed and examined. The *histopathologic* component involves cryopreserving this disc and cutting it in a horizontal fashion, then mounting sections onto glass slides, followed by staining and microscopic examination for residual tumor. This processing technique differs from standard excisions in which specimens are formalin-fixed, paraffin-embedded (FFPE) and cut in a "bread-loaf" fashion (Fig. 150.1B). Precise *mapping* entails marking any residual tumor on the map of the excision with the remaining positive area of tumor re-excised as indicated. This three-step process is repeated until there is no residual tumor identified microscopically. During this procedure, the Mohs surgeon has complete control of the excised tissue, including laboratory processing and interpretation of the tissue sections, as well as precise mapping. In the fourth step, *wound management*, the tumor-free defect is surgically closed or allowed to heal by second intention.

INDICATIONS FOR MOHS MICROGRAPHIC SURGERY FOR NON-MELANOMA SKIN CANCER (KERATINOCYTE CARCINOMA)
Tumor characteristics[1]

• Recurrent
• High-risk* anatomic location (Area H): "Mask areas" of the face (central face, eyelids, eyebrows, nose, lips, chin, ear, and periauricular skin/sulci, temple; Fig. 150.2), anogenital region, hands, feet, nail units, ankles, and nipples/areola
• Medium-risk† anatomic location (Area M): Face outside of area H, scalp, neck, pretibial leg
• Aggressive histologic subtype:
  • BCC: morpheaform (sclerosing), micronodular, basosquamous (metatypical), infiltrating
  • SCC: Breslow depth >2 mm, Clark level >III, deeply penetrating, poorly differentiated or undifferentiated‡, spindle cell, sclerosing, small cell, clear cell, lymphoepithelioma-like, sarcomatoid, acantholytic¶
• Perineural invasion
• Large size (>2 cm diameter)
• Poorly defined clinical borders (lateral and/or deep)
• Rapid growth
• Positive margin on recent excision

Characteristics of background skin
• Prior exposure to ionizing radiation • Chronic scar (Marjolin ulcer)
Patient characteristics
• Immunocompromised: solid organ transplant recipient, chronic lymphocytic leukemia, HIV infection, pharmacologic immunosuppression • Underlying genetic syndrome, e.g. xeroderma pigmentosum, basal cell nevus syndrome, Bazex–Dupré–Christol syndrome • Patient known to have previous high-risk tumors without other known health risk factors
*High risk for recurrence. †Medium risk for recurrence. ‡High degree of nuclear polymorphism, high mitotic rate, or low degree of keratinization. ¶Not included in the Appropriate Use Criteria (AUC) criteria[1].

Table 150.1 Indications for Mohs micrographic surgery for non-melanoma skin cancer (keratinocyte carcinoma). BCC, basal cell carcinoma; SCC, squamous cell carcinoma.

Downloaded for Anonymous User (n/a) at Egyptian Knowledge Bank from ClinicalKey.com by Elsevier on March 10, 2024. For personal use only. No other uses without permission. Copyright ©2024. Elsevier Inc. All rights reserved.

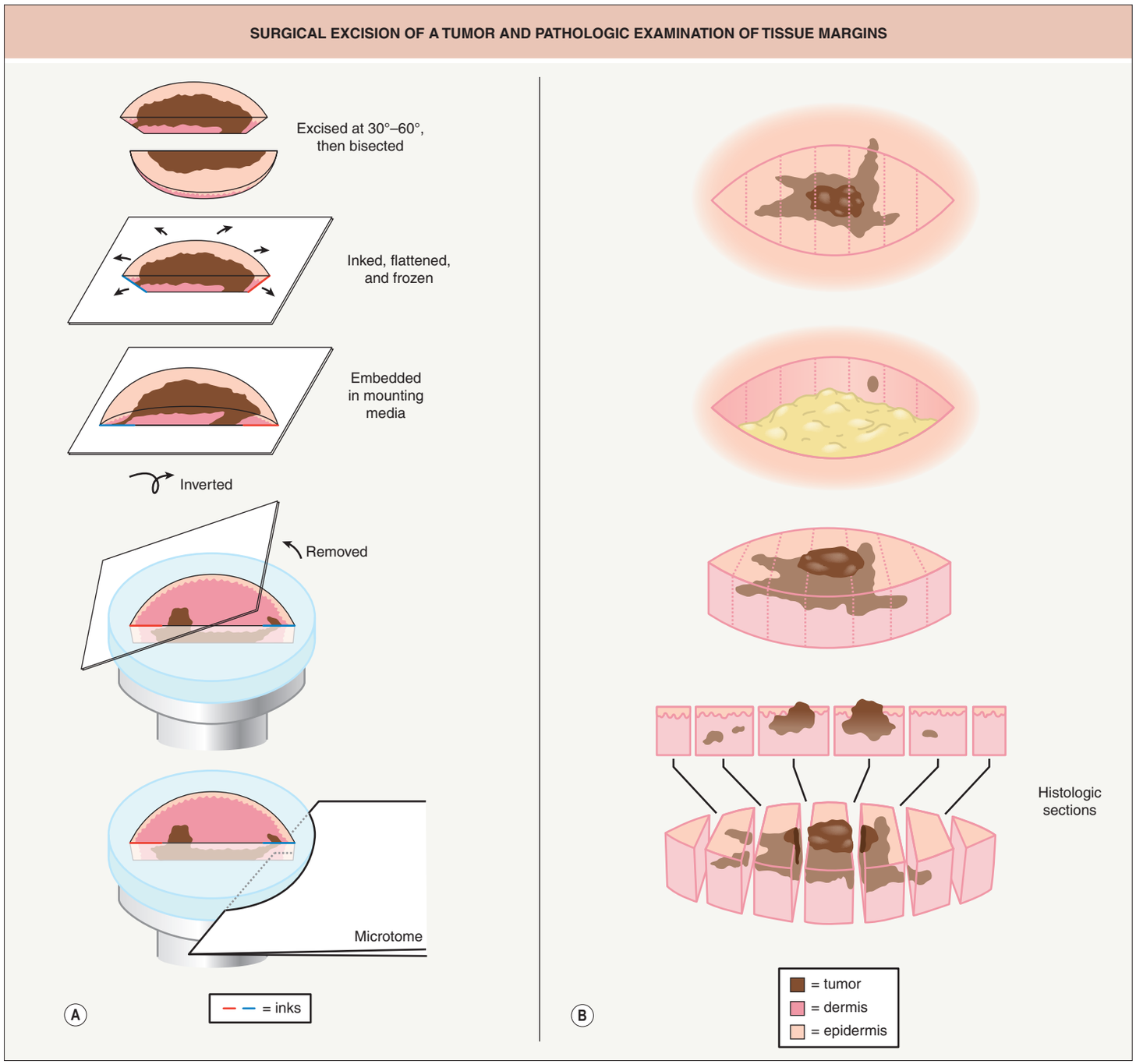

Fig. 150.1 Surgical excision of a tumor and pathologic examination of tissue margins. A Mohs micrographic surgery in which 100% of the total margin is examined. Following excision with a narrow margin, the specimen is flattened so that when the tissue is horizontally sectioned, the skin edge is in the same plane as the deep margin. Note the inversion of the tissue prior to sectioning. **B** Standard elliptical excision with vertical tissue sectioning ("bread loafing"). Histologically, the margins may appear clear even though there is still residual tumor.

HISTORY

Originally termed *chemosurgery*, MMS was developed by Dr Frederic E. Mohs at the University of Wisconsin-Madison and first published in 1941[2]. His original clinical technique involved the application of a zinc chloride paste to cancerous tissue 24 hours prior to surgical removal of the tumor. The paste fixed and isolated the tumor *in vivo*. Subsequently, the tumor was excised and processed in a manner similar to the technique used today. However, if there were residual tumor at the margins, zinc chloride paste was re-applied to cancerous margins for 24 hours prior to any further tissue resection. These steps were repeated until complete tumor clearance was obtained[3].

Limitations of this process include a long incubation period and tissue necrosis from the zinc chloride paste which renders wounds unsuitable for surgical reconstruction. The latter led to Dr Mohs' second major innovation – an objective analysis of second intention wound healing. Historically, surgical dogma held that second intention healing produced inferior cosmetic results compared to reconstruction, the surgeon's "first intention for healing". The acceptable, and at times superior, cosmetic outcome associated with second intention healing, particularly on concave surfaces, imparts its rightful place among valid reconstructive techniques.

Over 40 years ago, the zinc chloride-based, fixed tissue technique evolved into the fresh-frozen tissue technique[3], which was popularized by Tromovitch and Stegman[4]. The fresh-frozen section technique eliminated the need for the escharotic zinc chloride paste, and it allowed complete tumor clearance via multiple resections in a single day. Furthermore, without a zinc chloride-induced necrotic base, immediate

Downloaded for Anonymous User (n/a) at Egyptian Knowledge Bank from ClinicalKey.com by Elsevier on March 10, 2024. For personal use only. No other uses without permission. Copyright ©2024. Elsevier Inc. All rights reserved.

surgical reconstruction could be performed. The fresh tissue technique has now become the standard protocol for MMS.

TRAINING IN MOHS MICROGRAPHIC SURGERY

Training in MMS involves all aspects of cutaneous oncology, tumor resection, tissue preparation, histologic interpretation, and reconstruction. The substantial clinical, surgical, and histopathologic training received during a dermatology residency provides the background for specialized training in MMS. One of the unique advantages of Mohs surgical training is the degree of expertise in clinicopathologic correlation, which derives from dual training in both clinical and pathologic tumor assessment. The dermatologic surgeon must also acquire a mastery of cutaneous and soft tissue anatomy as well as reconstruction. MMS training programs differ depending upon the country, with a one-year Accreditation Council for Graduate Medical Education (ACGME) fellowships available in the US[5].

Both the American Board of Dermatology (ABD) and the American Osteopathic Board of Dermatology offer subspecialty certification in Micrographic Dermatologic Surgery. After 2025, a prerequisite for the ABD certifying examination will be completion of an ACGME-approved Micrographic Surgery and Dermatologic Oncology fellowship.

APPROPRIATE USE CRITERIA AND COST-EFFECTIVE CARE

In 2012, there was a multi-society collaboration to develop appropriate use criteria (AUC) for MMS[1]. For each of 270 clinical scenarios, a panel of surgical and medical dermatologists examined the rational use of MMS, taking into account multiple factors including size, behavior, and location (Fig. 150.2)[1,6]. In addition, tumors that did not require MMS, e.g. small basal cell carcinomas on the trunk, were identified (www.aad.org/education/appropriate-use-criteria/mohs-surgery-auc). The National Comprehensive Cancer Network (NCCN) guidelines for the treatment of cutaneous malignancies is also available as a reference[7].

Studies on the cost-effectiveness of MMS have produced variable results and conclusions, depending on the study location and methods[8,9]. When standard excision with FFPE sections and immediate repair is compared with MMS, the costs are either similar or the former is slightly less expensive than MMS. However, the cost-effectiveness of MMS is enhanced when the following factors are taken into account: the physical location of the surgical procedure (office-based vs. ambulatory surgery center or hospital), specimen processing (frozen vs. permanent sections), type and extent of reconstruction required (smaller defect size due to tissue-sparing vs. standard wide local excision), and the need for additional surgery for tumor recurrences[8–12]. Hopefully, application of MMS AUC[1] will lead to even greater cost savings.

INDICATIONS

Most skin cancers are locally invasive and, depending on their location, can invade vital structures such as the eye, nose, lips and ears, leading to significant tissue destruction. With time and neglect, metastasis may develop. The majority of non-melanoma skin cancers are low-risk and do not fulfill the criteria outlined in Table 150.1. For such tumors, cost-efficient superficial ablative techniques (e.g. electrodesiccation and curettage) or simple excision can be performed. Currently, ~25% of skin cancers are treated with MMS in the US[10]. MMS is well suited for skin cancers at high risk for recurrence and for those tumors located in regions requiring tissue conservation and complete margin control[10]. This includes large lesions in cosmetically sensitive areas.

Factors that identify a "high risk" skin cancer include clinical and histologic characteristics of the tumor, anatomic site, and history of prior treatment(s) (see Table 150.1). Because of the complete histologic examination of surgical margins, MMS allows tracking of unpredictable superficial or deep projections of tumor (see Fig. 150.1A). MMS is very useful for tracking tumors that involve embryonic fusion planes, the periorbital region, nerves, and bone. It is these deep and irregular tumor extensions that are primarily responsible for the higher recurrence rates observed with other techniques. Importantly, the indications for MMS are not absolute, and any treatment decision needs to be made in collaboration with the patient's preferences (e.g. local vs. general anesthesia for extensive procedures), performance status, and understanding of alternative treatment options and associated cure rates.

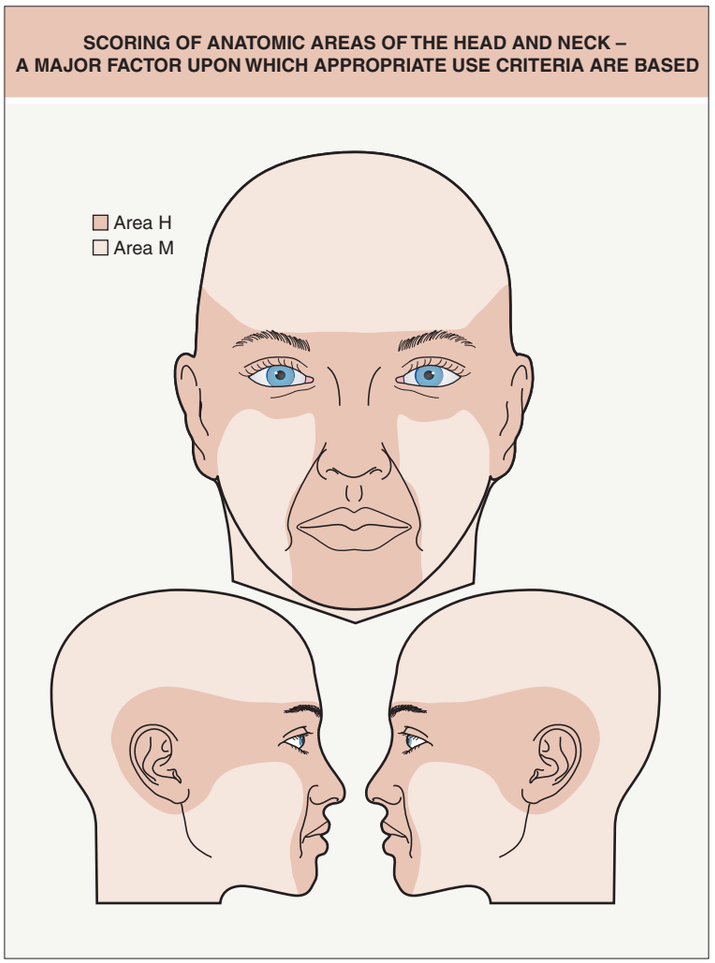

Fig. 150.2 Scoring of anatomic areas of the head and neck – a major factor upon which appropriate use criteria are based. Area H represents the anatomic sites with the highest risk for recurrence and the greatest need for tissue sparing, followed by Area M. The majority of the trunk and extremities is labeled as Area L (lowest need for tissue sparing and risk of recurrence), with the hand, foot, ankle, nail unit, nipple/areola, and anogenital region representing additional Area H sites and the shins an Area M site[1]. See www.aad.org/education/appropriate-use-criteria/mohs-surgery-auc as well as the Mohs AUC app.

The use of MMS for the more commonly managed cutaneous malignancies will be reviewed first, followed by its use for unusual neoplasms (Table 150.2).

Basal Cell Carcinoma

For primary BCCs, cure rates of 87% to 95% can be obtained with superficial ablative therapies and excision, especially on the trunk and extremities. In a meta-analysis by Rowe et al.[13], the 5-year cure rate for *primary* BCC treated with MMS was 99%, as compared to 90% to 93% using standard treatments (Table 150.3). For *recurrent* BCC treated with MMS, the 5-year cure rate was 90%–94% as compared to 80% for standard treatments (surgical excision, radiotherapy, cryotherapy, electrodesiccation and curettage)[14].

MMS provides superior cure rates for high-risk BCCs that are more likely to recur, including those that are large in size (>2 cm) or have aggressive histologic subtypes (e.g. basosquamous carcinoma[38]) or perineural invasion[39,40].

Squamous Cell Carcinoma

MMS offers the highest cure rates for patients with high-risk primary or recurrent SCCs. The local recurrence rates, based on a retrospective review of MMS versus non-MMS modalities for primary SCC, are outlined in Table 150.3[16].

Downloaded for Anonymous User (n/a) at Egyptian Knowledge Bank from ClinicalKey.com by Elsevier on March 10, 2024. For personal use only. No other uses without permission. Copyright ©2024. Elsevier Inc. All rights reserved.

MMS is indicated for management of SCCs with one or more risk factors for recurrence or metastasis (see Table 150.1). These indications include large SCCs (>2 cm), recurrent tumors, incompletely excised SCCs, and tumors with ill-defined clinical margins, rapid growth, an aggressive histologic subtype, and/or perineural invasion (Fig. 150.3), as well as SCCs arising in chronic scar tissue (Marjolin ulcer)[41]. Immunosuppressed patients, including those with solid organ transplants and chronic lymphocytic leukemia, as well as patients receiving medications such as voriconazole and unopposed vemurafenib, can develop rapidly growing SCCs that benefit from MMS.

In addition, SCCs arising in high-risk anatomic sites may be managed with MMS. For example, tumors of the lip have a high propensity for recurrence and metastasis with cure rates as high as 92% achieved with MMS[42]. MMS is also well suited for SCCs occurring in anogenital areas and on the digits, where tissue conservation is important. When compared with conventional methods, MMS for the treatment of penile SCC offers comparable survival rates. Prior to MMS, SCCs involving the nail unit were often treated with amputation or radiation. MMS provides an excellent choice for treatment of periungual and subungual SCC without osseous involvement, with cure rates of up to 96%[43].

Erythroplasia of Queyrat (EQ) is a term used for SCC *in situ* (SCCIS) arising in anogenital mucosae, especially in men. An erythematous thin plaque is typically seen on the inner surface of the foreskin, glans penis, and/or coronal sulcus of an uncircumcised man (see Chs. 73 & 108). In women, differentiated vulvar intraepithelial neoplasia (dVIN) and high-grade squamous intraepithelial lesion (HSIL) are the preferred terms, with oncogenic human papillomaviruses (HPVs) often playing an etiologic role in the latter. HPV infection also increases the risk of anogenital SCC in immunosuppressed individuals (e.g. HIV-infected).

MMS is an effective treatment for EQ, with a 5-year cure rate of 90%[17]. When excising EQ of the glans penis, Mohs layers should be very thin in order to minimize entry into and resection of the corpus spongiosum and cavernosum. If either is entered, achieving hemostasis can be challenging. EQ can often extend into the urethra and differentiation of SCCIS from transitional epithelium is often difficult on frozen sections. With deep extension along the urethra, collaboration with a urologist and completion of the surgery under general anesthesia are recommended.

CUTANEOUS TUMORS TREATED WITH MOHS MICROGRAPHIC SURGERY AND REPORTED CURE RATES	
Cutaneous tumors	**Cure rates (5-year)**
Basal cell carcinoma	99% (primary tumors)[13] 90%–93% (recurrent tumors)[14]
Squamous cell carcinoma	92%–99% (primary tumors)[15] 90% (locally recurrent tumors)[16]
Erythroplasia of Queyrat	90%[17]
Cutaneous melanoma *in situ*, including lentigo maligna	67%–100%[19–24]
Atypical fibroxanthoma	93%–100%[25]
Dermatofibrosarcoma protuberans	97%–100%[26–29]
Merkel cell carcinoma	84%[30]
Microcystic adnexal carcinoma	90%[31–33]
Sebaceous carcinoma	89%[34]
Extramammary Paget disease	92%–97%[35,36]
Leiomyosarcoma (superficial)	87%[37]

Table 150.2 Cutaneous tumors treated with Mohs micrographic surgery and reported cure rates. For eccrine porocarcinoma, angiosarcoma and lymphoepithelioma-like carcinoma, efficacy based only upon case reports. For mucinous eccrine carcinoma, increased efficacy relative to wide excision not established. Some surgeons also use Mohs surgery for invasive cutaneous melanoma.

FIVE-YEAR CURE RATES FOR PRIMARY BCC AND SCC		
Treatment modality	**5-year cure rate**	
	BCC (%)	**SCC (%)**
Surgical excision	90	92
Electrodesiccation & curettage	92	96
Radiation	91	90
Cryotherapy	93	N/A
All non-Mohs modalities	91	92
Mohs micrographic surgery	99	97

Table 150.3 Five-year cure rates for primary basal cell carcinoma (BCC) and squamous cell carcinoma (SCC) by treatment modality. Based upon refs 1 and 4. There is some inherent bias in these data as the studies quoted in this table did not all use the same patient selection criteria. For example, techniques such as electrodesiccation and curettage appear to have higher cure rates for SCC than does excision to the adipose layer, but it is likely that patients who had curettage selected as a definitive treatment had superficial tumors. N/A, not available.

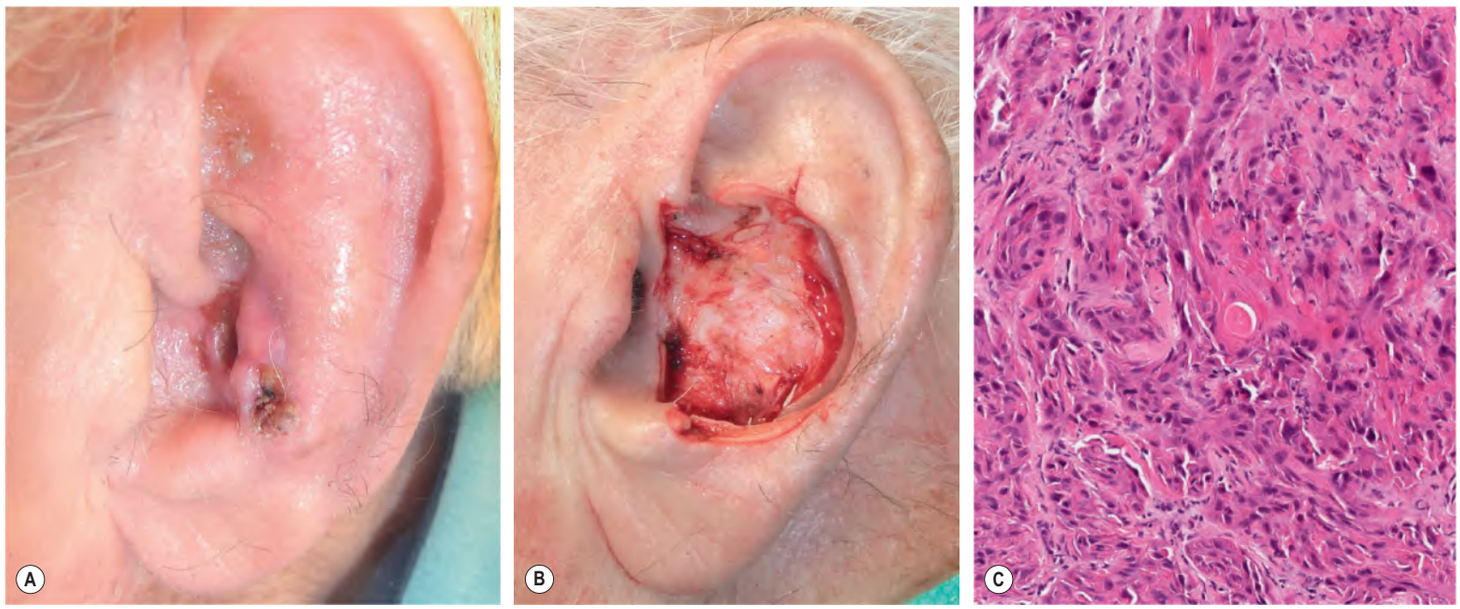

Fig. 150.3 Recurrent, biopsy-proven, moderately differentiated squamous cell carcinoma (SCC) of the left conchal bowl. A Prior to Mohs micrographic surgery. **B** Tumor extirpation resulted in a through-and-through defect of the ear. **C** Histologic features of this aggressive SCC include nests and cords of polygonal cells with enlarged, pleomorphic nuclei and only small foci of keratinization.

Downloaded for Anonymous User (n/a) at Egyptian Knowledge Bank from ClinicalKey.com by Elsevier on March 10, 2024. For personal use only. No other uses without permission. Copyright ©2024. Elsevier Inc. All rights reserved.

Keratoacanthomas (KAs) classically grow quickly and then can spontaneously involute. However, management of KAs remains controversial[18]. Microscopically, some KAs are difficult to distinguish from SCC and there are reports of non-regressing and metastatic KAs, implying that the tumor was actually an SCC. Currently, most KAs are considered to be well-differentiated SCCs. MMS may be particularly beneficial for large lesions, as well as those occurring in anatomically sensitive areas.

Verrucous carcinoma is considered a variant of SCC, and it can be associated with HPV infection. Tumors most commonly occur in the oral cavity, on the plantar foot, or on the penis (see Ch. 108). While generally considered a low-grade carcinoma, there are reports of metastasis. Histopathologic interpretation of frozen sections can be challenging because the tumor cells are very well differentiated with minimal nuclear atypia, making distinction from pseudoepitheliomatous hyperplasia, verruca vulgaris, or condyloma acuminatum challenging. In patients with a clear-cut clinical diagnosis verified by histologic examination, the irregular architectural pattern of verrucous carcinoma may aid in evaluating the margins of excision by MMS.

Cutaneous Melanoma

Melanoma in situ *(lentigo maligna) of the head and neck region*

Treatment of melanoma *in situ* (MIS), in particular lentigo maligna (LM), of the head and neck region is a subject of debate. Controversies include width of surgical margins, MMS versus standard surgical excision, and use of pre- or postoperative topical imiquimod. Even within MMS, there are different techniques, from classic MMS with frozen sections to "slow Mohs" utilizing "rush" permanent sections. Reasons for the debate include: (1) the difficulty in distinguishing atypical melanocytes of photodamaged skin from melanoma cells (Fig. 150.4), especially in frozen sections stained with H&E or antibodies that recognize melanosomes; and (2) the natural history and prognosis of LM. The first can lead to residual tumor or unnecessary excision of photodamaged skin while the second can complicate determining an impact on survival.

Current NCCN guidelines recommend surgical treatment with margins of 0.5–1.0 cm, allowing for narrower margins depending upon anatomical and functional considerations[44]. However, LM treated with surgical excision alone may require wider margins as lesions tend to be ill-defined with subclinical spread[44] and a local recurrence rate of 6%–20% has been reported with standard excision[45]. Although still employed in a minority of patients, the use of MMS to treat cutaneous melanoma has increased over the past two decades, from 2.6% (2001) to 7.9% (2016)[46].

There are no randomized controlled trials comparing wide local excision (WLE) versus MMS to treat MIS of the head and neck region. Database studies, including a retrospective review of a prospective database that compared H&E-based MMS with WLE[24], reported comparable rates of overall and melanoma-specific survival. In the retrospective review, there was also no difference in recurrence rates[24]. Studies from single institutions have also observed low recurrence rates[21–23], e.g. <1% with a mean follow-up of 2.8–3.7 years[21,22].

As noted previously, distinguishing atypical melanocytes of photodamaged skin from melanoma cells in frozen sections can prove challenging. In addition to similar cellular features, processing artifacts (e.g. freeze-induced vacuolization within keratinocytes that resembles vacuolization in melanocytes) may lead to misinterpretation[47]. Detection of a transition zone between photodamaged skin and MIS in FFPE vertical sections can assist in determining clear margins, but this is not possible with *en face* processing of LM margins. To address this potential problem, a prospective cohort study (n = 167) was conducted that examined the accuracy of MIS margin assessment with MMS and H&E-stained frozen sections; the authors reported an accuracy rate of 95%[48]. The latter was determined by excising an additional 1 mm margin followed by its examination by a dermatopathologist. Other approaches include: (1) vertically processing the central debulk plus a narrow margin[22]; (2) obtaining shallow biopsies from the patient's normal-appearing adjacent skin or both perilesional and distant skin[49]; and (3) examination of FFPE tissue margins to confirm that the final MMS margin is negative[50,51].

Potential improvements include immunohistochemical (IHC) staining with antibodies that recognize melanocyte-specific transcription factors (e.g. MITF) rather than melanosomal proteins (e.g. Melan-A/MART-1) (Table 150.4). This prevents staining of melanosome-containing keratinocytes and overestimating the density of melanocytes within photodamaged skin[52] as well as falsely diagnosing pigmented actinic keratoses as LM. Of note, in a survey of Mohs surgeons, only 36% felt comfortable interpreting MART-1-stained frozen sections and a need for additional education was noted as was recognition that formal training is not offered in all fellowship training programs[53].

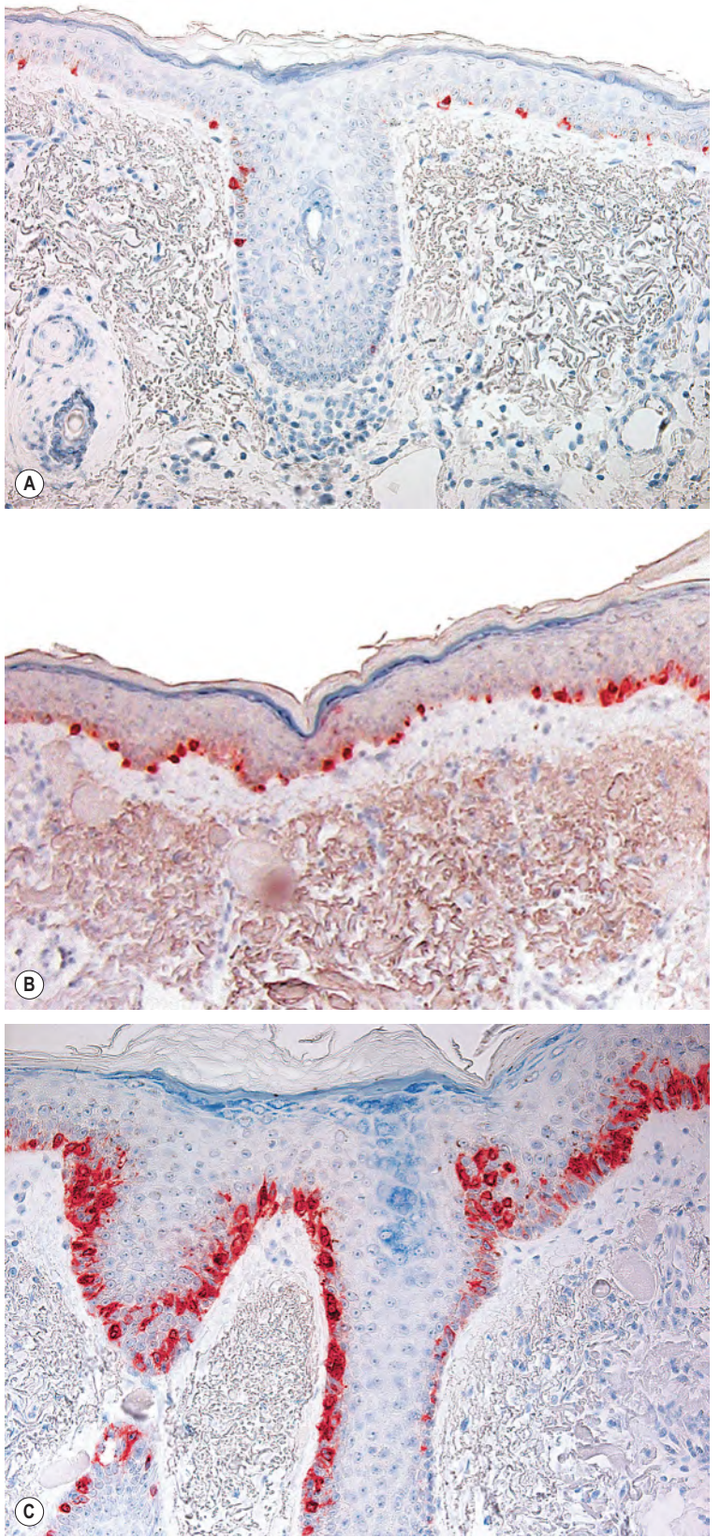

Fig. 150.4 Immunostaining with Melan-A/MART-1. A Normal density of melanocytes. **B** Melanocytic hyperplasia with scattered atypical melanocytes in sun-damaged skin. **C** Lentigo maligna with atypical melanocytic proliferation, some pagetoid spread, and adnexal extension. *Courtesy Clark C. Otley, MD, and Randall K. Roenigk, MD.*

Downloaded for Anonymous User (n/a) at Egyptian Knowledge Bank from ClinicalKey.com by Elsevier on March 10, 2024. For personal use only. No other uses without permission. Copyright ©2024. Elsevier Inc. All rights reserved.

SPECIAL AND IMMUNOHISTOCHEMICAL STAINS USED IN MOHS MICROGRAPHIC SURGERY							
	SCC*	BCC	DFSP	EMPD	Sebaceous carcinoma	Melanoma†	MAC
Special stains	–	Toluidine blue	–	PAS	Oil red O‡	–	Toluidine blue[e1]
Immunohistochemical stains	AE1/AE3 (inset) 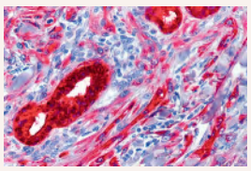	AE1/AE3, Ber-EP4	CD34	CK7, CEA	Adipophilin, CK (e.g. AE1/AE3)	MITF, Melan-A/MART-1 (Fig. 150.4), Mel-5, SOX10, HMB45	CK (e.g. AE1/AE3)

*To detect perineural invasion and high-risk histologic subtypes, e.g. infiltrating, spindle cell, single cell.
†Includes lentigo maligna and other types of melanoma *in situ*.
‡Being replaced by adipophilin stain.

Table 150.4 Special and immunohistochemical stains used in Mohs micrographic surgery. AE1/AE3, pankeratin marker; Ber-EP4, stains cellular glycoproteins in BCCs, sweat glands, and some hair follicles; BCC, basal cell carcinoma; CEA, carcinoembryonic antigen; CK7, cytokeratin 7; DFSP, dermatofibrosarcoma protuberans; EMPD, extramammary Paget disease; MAC, microcystic adnexal carcinoma; MART-1, melanoma antigen recognized by T cells; MITF, microphthalmia transcription factor (nuclear stain); PAS, periodic acid Schiff; SCC, squamous cell carcinoma. *Photomicrograph: Courtesy Luis Requena, MD.*

Invasive melanoma

Based on large randomized controlled trials (RCTs), WLE with recommended margins is the gold standard for treatment of invasive melanoma (see Ch. 113). In patients undergoing sentinel lymph node biopsy, the WLE is routinely performed in tandem[54]. Cutaneous melanomas in general are well-defined, with the exception of some cases of LM and acrolentiginous melanoma. For locally recurrent melanomas, ill-defined or amelanotic melanomas, or melanomas in anatomic sites such as the genitalia, digits, eyelids, nose and ears, a multidisciplinary approach that includes MMS can be considered. There is also some evidence suggesting the utility of MMS for thin melanomas[11,19,55,56].

Staged excisions ("slow Mohs") for melanoma

One variant of MMS is staged excisions ("slow Mohs")[50,51,57] in which the tissue specimen is sent for "rush" FFPE sections that are read by a dermatopathologist the next day. The wound is kept open and covered with a pressure dressing. Some surgeons debulk the visible tumor and determine its depth via vertical processing while assessing the peripheral margin in an *en face* fashion, whereas others cut the tissue radially, allowing the pathologist to appreciate the transition from tumor to actinically damaged skin. If there is residual melanoma, another layer is removed until a negative (tumor-free) margin is achieved. The obvious major disadvantage is the inconvenience of a multi-day procedure. Reported recurrence rates range from <1% to 7.3%, with follow-up ranging from 3 to 57 months[45,58].

Additional staged-excision techniques include the square technique[59], geometric staged excision[60], and the spaghetti technique[61]. In the ***square technique***, two closely spaced, parallel blades are used to create a square-shaped defect (thin and frame-like) with the tumor and presumed adequate margins left intact. If the excised peripheral tissue has clear margins, then the central square is removed surgically[59]. When the square technique was used to treat 834 melanomas, the mean margin required for histologic clearance was 9.33 mm for MIS and 13.7 mm for invasive melanoma. With a median follow-up of 9.3 years, the projected recurrence rate was 2.2% at 10 years[62].

In the ***geometric staged excision***[60], the entire specimen is excised in a geometric pattern; the margins are inked and strips are cut off along the margins. The cut strips are oriented, processed and cut *en face* while the central portion is cut vertically to determine tumor depth. As a result, the entire peripheral margin is examined, which is where the tumor may extend a significant distance from the clinically apparent lesion. In addition, the vertical sections of the central portion confirms or adjusts the tumor thickness. Some dermatopathologists prefer this method because it may be easier to process the tissue for examination of the entire peripheral epidermal and dermal margin[63,64]. In the ***spaghetti technique***, thin strips at the peripheral margin of the visible tumor are excised in stages until the whole tumor is mapped out, then the central lesion is removed. This allows for closure between each stage. A local recurrence rate of 4.76% at a median follow-up of 25 months has been reported[61].

A potential disadvantage of the square and geometric pattern techniques is that a few extra millimeters of skin are sacrificed in order to provide the straight lateral margins. For small tumors, this difference is marginal but if several layers are required and/or the tumor is irregularly shaped, reconstruction can become more complex.

Currently, evidence-based support for the use of MMS to treat cutaneous melanoma is limited by single institution experiences, inclusion of heterogenous tumor types, variable (and sometimes limited) observation periods, and outcome measures based upon local recurrence rates. Given the natural history of LM, the latter can be problematic. Whether a multi-center, randomized, controlled, prospective trial comparing WLE with MIS will ever be conducted remains uncertain.

Uncommon or Rare Cutaneous Neoplasms

Due to the relative rarity of these uncommon tumors, the efficacy of MMS is based primarily on case series from a single institution or case reports.

Atypical fibroxanthoma/pleomorphic dermal sarcoma

Atypical fibroxanthoma (AFX) is a dermal-based mesenchymal neoplasm that develops within photodamaged skin and has minimal, if any, metastatic potential (see Ch. 116). Tumors with similar pathologic features but which demonstrate subcutaneous invasion, necrosis, and/or lymphovascular or perineural invasion are associated with a worse outcome and are referred to as pleomorphic dermal sarcoma (PDS). Typically, AFX presents as a nodule in the head and neck region of an elderly person with significant actinic damage. Its histologic features are said to be relatively easy to identify in frozen sections. For AFX, MMS has been reported to result in lower recurrence rates and greater tissue preservation whereas in PDS, the data is limited[65].

Dermatofibrosarcoma protuberans

Dermatofibrosarcoma protuberans (DFSP) is a slowly growing, locally aggressive soft tissue sarcoma that most often arises on the trunk of young to middle-aged adults (see Ch. 116). It typically extends in an irregular fashion beyond the clinically visible tumor margins. Based upon pooled raw data collected over a 20-year period, recurrence rates following WLE have ranged from 6% to 60% versus 1% to 3% following MMS[26,66–68]. A possible explanation for this difference is the inclusion of patients with primary DFSP, recurrent DFSP, and DFSP with fibrosarcomatous changes, which can lead to biased results as patients with more aggressive disease tended to have WLE (compared to MMS)[66–68]. Of note, a recent retrospective, multicenter study comparing MMS vs. WLE for DFSP on the trunk and extremities found no difference in outcomes[69] while emphasizing the need for complete resection with precise margin control[70]. In the head and neck region, MMS can be advantageous given the potential for conserving tissue while offering margin control[71].

DFSP is often a large-sized tumor and as a result, MMS can be a time-consuming procedure. If tumor identification proves difficult in frozen sections, staged excision ("slow Mohs"; see above), utilizing anti-CD34 IHC staining, can be performed[72,73].

Downloaded for Anonymous User (n/a) at Egyptian Knowledge Bank from ClinicalKey.com by Elsevier on March 10, 2024. For personal use only. No other uses without permission. Copyright ©2024. Elsevier Inc. All rights reserved.

Merkel cell carcinoma

Merkel cell carcinoma (MCC) is a very aggressive malignancy, often arising in older adults with photodamage or who are immunosuppressed (see Ch. 115)[74]. Clinically, the tumor usually presents as a pink–red to violaceous papulonodule that favors the head and neck region. Microscopically, the tumor cells are aggregated into large sheets, allowing them to be easily identified in frozen sections. NCCN guidelines recommend WLE plus sentinel lymph node biopsy (SLNB) followed by radiotherapy to the primary site and regional lymph nodes (unless the lesion is low risk [≤1 cm on the trunk or an extremity with no lymphovascular invasion and negative surgical margins in the setting of a negative SLNB]; (see Fig. 115.19). However, a database study found that patients who underwent MMS were less likely to have a sentinel lymph node biopsy performed[75]. That said, when 22 MCCs were removed via MMS, positive margins were noted in 57% of the cases despite the surgical margins taken meeting or exceeding NCCN guidelines of 1–2 cm margins; however, 92% of the positive cases involved the deep margin[76].

Microcystic adnexal carcinoma

Microcystic adnexal carcinoma (MAC) is a locally aggressive tumor that typically involves the face of older adults (Fig. 150.5). Histologically, it has an infiltrative growth pattern with frequent perineural invasion (Fig. 150.6). With an overall recurrence rate reported in the literature approaching 40%, MMS offers an advantage. Based upon several studies, a five-year cure rate of 90% has been observed following MMS (see Table 150.2)[31]. In one of these studies, defects following MMS were four times larger than clinical estimates[32].

Sebaceous carcinoma

Sebaceous carcinoma can develop in any site that contains sebaceous glands, but it has a predilection for periocular skin. MMS is often employed for tumors in the latter location. Based upon a review of the literature, WLE of sebaceous carcinomas was associated with a local recurrence rate of 4%–37% and a nodal metastatic rate of 3%–28%[77]. In comparison, MMS had a local recurrence rate of 11% (2 of 18 patients) with nodal metastases developing in 1 patient[34]. A more recent

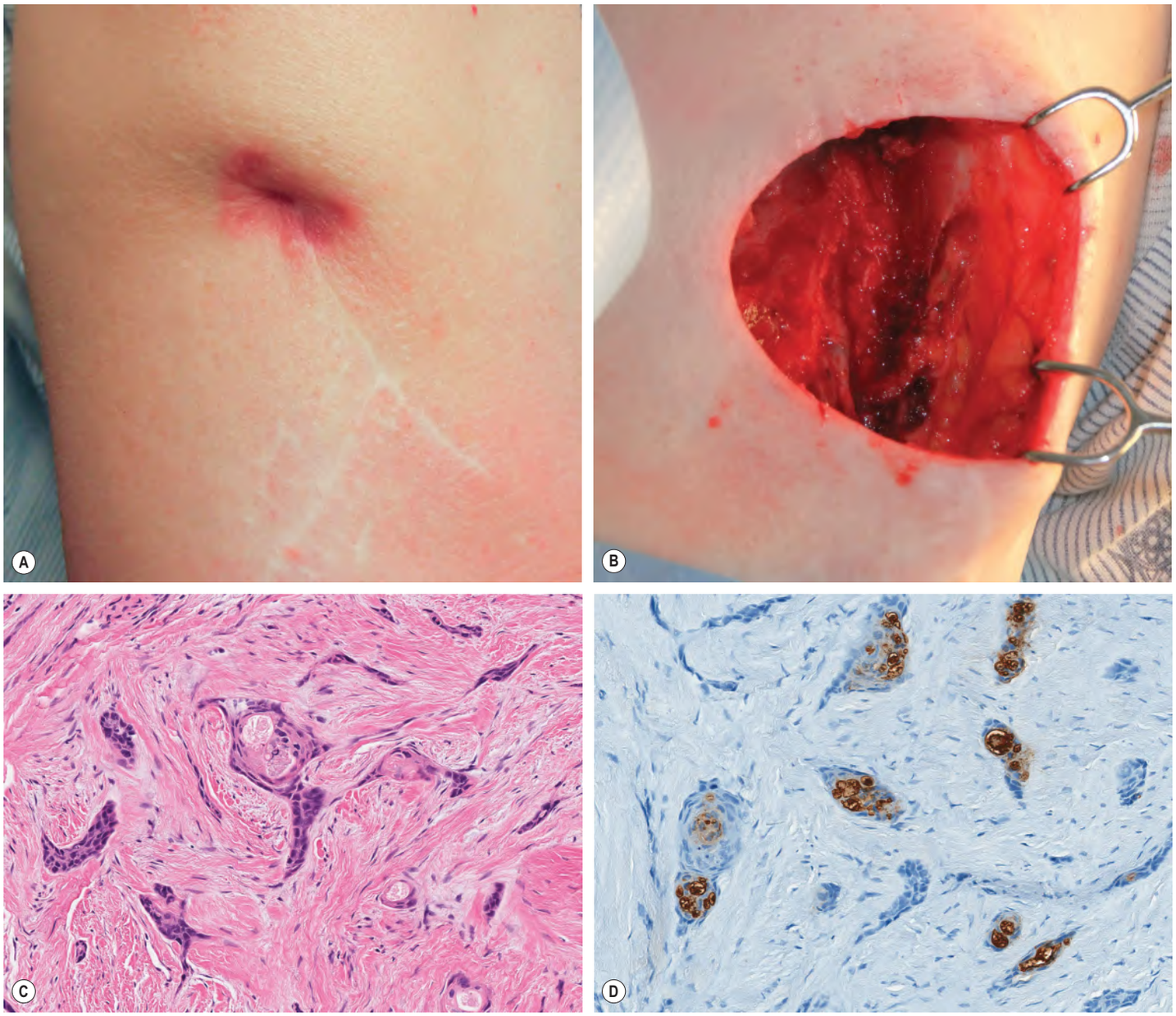

Fig. 150.5 Recurrent basal cell carcinoma (BCC) plus microcystic adnexal carcinoma (MAC). A Recurrent, biopsy-proven BCC of the right upper lateral arm that had been previously treated four times (electrodesiccation and curettage; excision; Mohs micrographic surgery [MMS] twice) over a twenty-year period. An indurated nodule was present at the scar site. **B** Defect after two MMS stages; there was deep infiltration of the subcutaneous tissue, muscle, and periosteum of the humerus. **C** Histologically, small infiltrative basaloid tumor strands embedded within a desmoplastic stroma were seen; there was also ductal differentiation. Because the possibility of a coexisting MAC was raised, the tissue was thawed and submitted for formalin-fixed paraffin-embedded (FFPE) sections. **D** Immunohistochemical staining of FFPE sections demonstrated CEA-positivity of ductal cells, supporting the diagnosis of MAC.

Downloaded for Anonymous User (n/a) at Egyptian Knowledge Bank from ClinicalKey.com by Elsevier on March 10, 2024. For personal use only. No other uses without permission. Copyright ©2024. Elsevier Inc. All rights reserved.

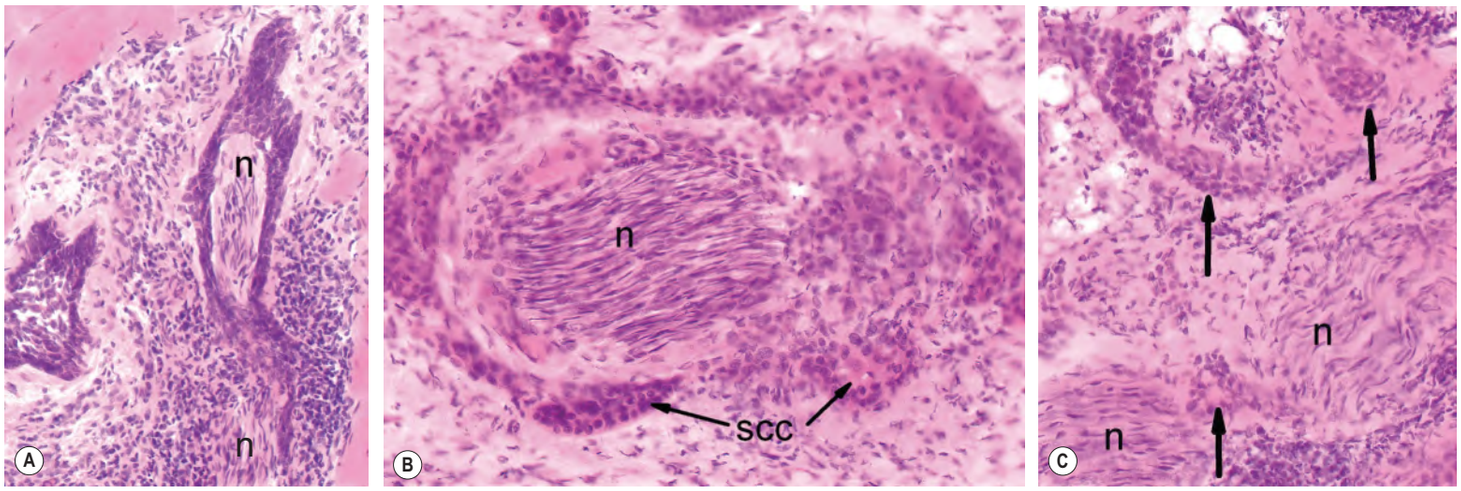

Fig. 150.6 Perineural involvement by various cutaneous tumors (frozen sections). A Basal cell carcinoma with a halo of basal cells enveloping a cutaneous nerve (n). **B** Squamous cell carcinoma (SCC) surrounding nerve fiber (n). **C** Microcystic adnexal carcinoma with perineural invasion by dominant pilar structures (arrows) in the deep subcutaneous portion of the tumor; n, nerve. *Reproduced with permission from Snow S. Atlas of Mohs Surgery Frozen Sections. Madison, WI: Scope Publishing, 2010.*

retrospective review of 45 sebaceous carcinomas treated with MMS found no local recurrences, metastases, or disease-specific deaths, with a mean follow-up of 3.6 years[78]. One challenge associated with these tumors is discontiguous growth, which can thwart any method of histologic margin evaluation. The removal of an extra safety margin of tissue for permanent sections is a reasonable strategy.

Other adnexal carcinomas

This group consists of the uncommon tumors that have sweat gland (eccrine, apocrine), sebaceous gland, or follicular differentiation and includes mucinous carcinoma, eccrine porocarcinoma, adenoid cystic carcinoma, papillary adenocarcinoma, and trichilemmal carcinoma (see Ch. 111). These tumors are usually locally destructive with extensive unpredictable local tissue invasion and therefore have a high rate of local recurrence following excision. Typically, their microscopic features are readily recognizable in frozen sections so they are amenable to MMS[79]. Rapid IHC staining can aid in diagnosis (see Table 150.4).

Miscellaneous tumors

MMS has been utilized for other malignant neoplasms, including angiosarcoma, lymphoepithelioma-like carcinoma, leiomyosarcoma and extramammary Paget disease, as well as cutaneous breast metastases[35–37,80,81]. Occasionally MSS is employed for benign tumors that have a predilection for recurrence such as infantile digital fibroma, desmoplastic trichoepithelioma, and granular cell tumor. Rarely, it is used to eradicate drug-resistant cutaneous fungal infections.

CONTRAINDICATIONS

Discontiguous tumors can lead to the problem of false-negative margins, both with MMS and with WLE. Therefore, this feature is not an absolute contraindication. When the tumor cells cannot reliably be identified in frozen sections this is a relative contraindication. If patients are unwilling or unable to undergo surgery that is time intensive, then standard excision or a non-surgical approach such as radiotherapy may be a better option. However, for some patients with serious medical problems, MMS done under local anesthesia may be safer than surgery performed under general anesthesia[82–84].

PREOPERATIVE HISTORY AND CONSIDERATIONS

A history and focused skin examination should be performed at the time of consultation, which can be the same day as the surgical procedure. The pathology report should be reviewed and, if the diagnosis appears questionable, the histologic sections should be re-examined. Indications for antibiotic prophylaxis should be evaluated and then reviewed with the patient's primary physician, cardiologist or orthopedic surgeon if necessary (see Table 151.2)[85]. Similarly, the management of any implanted electronic medical device as well as anticoagulants and antiplatelet agents needs to be addressed (see Ch. 151).

A thorough review of allergies, including past reactions to antibiotics, local anesthetics, povidone–iodine preparations, latex and adhesives, is conducted. MMS routinely employs only local anesthetics (see Ch. 143), but depending upon the patient oral anxiolytics may also be prescribed. Although lidocaine allergy is rare, the surgeon should be prepared for an emergency response if required.

Upon completion of the medical evaluation, the Mohs surgeon should explain the nature of the tumor, therapeutic options, the key features of MMS, and repair options. In order to prevent wrong-site surgery, photographs of biopsy sites are strongly encouraged. Visualization and confirmation of the biopsy site with the patient are essential[86]. Following informed consent, a standardized time-out is taken prior to the procedure. Patients should be encouraged to continue regular medications and eat a light meal on the morning of surgery, unless conscious sedation is planned.

Individuals with extremely large, recurrent, fixed, deeply invasive tumors and/or clinical signs of perineural invasion can benefit from preoperative radiologic imaging[87,88]. For detection of perineural invasion and intracranial extension (including meningeal), magnetic resonance imaging (MRI) represents the most sensitive imaging modality. However, detection of small nerve involvement is limited and immediate post-resection changes may distort findings. A computed tomography (CT) scan is more sensitive in identifying subtle bone erosion while both CT and MRI are used to evaluate regional lymph nodes.

Very complex cases requiring a multidisciplinary approach should be evaluated preoperatively by other subspecialties (e.g. oculoplastics, otolaryngology, neurosurgery, plastic surgery, radiation oncology) as needed. Following removal of the tumor by or with the assistance of the Mohs surgeon, the most appropriate specialist performs the repair.

TECHNIQUE

Table 150.5 provides a flow sheet for performing MMS and Fig. 150.7 depicts the procedure. (Also see Video 150.1)

VARIATIONS/REFINEMENTS

There are several modifications/variations of MMS that are used to improve: the speed of tissue processing[89]; the efficiency of tumor removal; and the recognition of individual tumor cells for better margin control. For descriptions of staged-excision ("slow Mohs") techniques, see the Cutaneous Melanoma section.

The *single section method* can be used for smaller tumors[90]. It consists of a highly beveled specimen with relaxing incisions on the superior, tumor-bearing portion to allow all peripheral edges to fold outward into a single plane. This method is particularly useful for tumors in which a shallow Mohs layer can be taken and then the surgical defect

Downloaded for Anonymous User (n/a) at Egyptian Knowledge Bank from ClinicalKey.com by Elsevier on March 10, 2024. For personal use only. No other uses without permission. Copyright ©2024. Elsevier Inc. All rights reserved.

allowed to heal by second intention. The unaltered examination of the complete deep margin also reduces the possibility of missed deep margins due to tissue subdivision.

A *non-beveled 90° incision* can be used for MMS on the extremities. The resulting vertical edges are ideal for reconstruction. Although a traditional beveled edge can be trimmed prior to reconstruction, a true, sharp, straight 90° angle is more difficult to obtain. Disadvantages include excision of more tissue and the necessity to manipulate the specimen to make the tissue flatten into a single plane.

In *wide excision MMS* ("wide Mohs"), a larger, clinically tumor-free margin (5–20 mm) is taken. It can be used for tumors that have a high propensity for recurrence or metastases (including satellite metastases), in particular melanoma, Merkel cell carcinoma, and cutaneous sarcomas[17]. In these scenarios, margin control is prioritized over tissue sparing[5].

During MMS, *rapid immunohistochemical (IHC) staining* can be utilized to assist in histologic evaluation (see Table 150.4)[91]. Some surgeons find it especially helpful for challenging and high-risk tumors[52,92,93]. However, there has been rather limited adoption of IHC staining by Mohs surgeons due to the additional cost and time required as well as concerns regarding reliability. In a 2013 survey of Mohs surgeons, only 22% of the respondents (n = 378) incorporated IHC staining into their practice following fellowship training[53].

CHALLENGES AND PITFALLS

The success of the procedure is dependent upon the precision and meticulousness of each step. Recurrences following MMS have been linked to inherent tumor characteristics such as morphology, size or location as well as errors in the procedure[94]. Errors encountered during MMS can be divided into technical (e.g. excess epidermal tissue in the central portion of the layer pushed down to cut margin and interpreted as tumor, incorrect bevel angle or relaxing incisions) and pathologic interpretation (Fig. 150.8)[95,96]. A limitation of MMS arises when the invasiveness of the tumor prevents continued tracking and consultation with the appropriate surgical specialist is indicated.

There are several clinical scenarios in which it is appropriate to send tissue for FFPE including: (1) a second opinion is required during removal of a cutaneous melanoma; (2) further assessment is needed of an aggressive, deep, or histologically unusual tumor; (3) confirmation of the presence of a different tumor than was diagnosed preoperatively (Figs. 150.5 and 150.9); (4) a significant amount of tissue is available for complete staging of the primary tumor; (5) unusual histologic findings in the frozen sections require a second opinion; (6) frozen section interpretation is insufficient to assess the tissue margin reliably; (7) a tumor diagnosed solely by frozen section prior to surgery, i.e. no preoperative biopsy was sent for routine histology; or (8) special stains

MOHS MICROGRAPHIC SURGERY (MMS) FLOW SHEET
Preoperative assessment
• Upon arrival, the patient's demographic information is confirmed, allergies, pertinent medications and vital signs are recorded, and the preoperative biopsy is reviewed • Any prophylactic antibiotic, anti-anxiety drug or cardiac device is either administered or managed as needed • The tumor is closely examined (Fig. 150.7A) and the clinical margin is marked (e.g. with gentian violet) • Reference to diagrams, landmarks and photographs is made to ensure correct site identification and every patient is asked to confirm the tumor location with a mirror[86] • The planned procedure and possible reconstruction are reviewed and consent obtained
Preparation of the site and first Mohs surgery layer

• The site is then wiped with alcohol, local anesthetic (see Ch. 143) is infiltrated, and the site is prepped with chlorhexidine or povidone–iodine
• The central portion of the tumor is de-bulked with a curette to further define subclinical tumor extension (Fig. 150.7B); this step may be omitted when tumors are very small or on thin eyelid skin
• The first MMS layer includes all clinically evident tumor plus a small margin of normal-appearing tissue (Fig. 150.7C)
  • Depending on the histologic subtype and likelihood of subclinical tumor extensions, the margin of normal skin may range from 1 to 10 mm
  • For shallow tumors or those at sites favorable for second intention healing, the first MMS layer is planned as a shallow excision
  • For deep tumors or at sites where second intention healing is not a good option, a full-thickness excision to subcutaneous fat is performed
• For recurrent tumors, the most thorough approach is to resect all tissue involved by the previous treatments, including the primary site and reconstruction scar; if the recurrence is clearly isolated to only one site and/or complete resection would cause difficulties, then a localized resection of the clinically recurrent area can be considered
• When excising the MMS layer, the scalpel is held at a 30–60° angle to the skin surface to create a beveled incision (Fig. 150.7C)
• Before the layer is completely removed, both the layer and the adjacent surrounding tissue are marked with shallow scalpel cuts or a marking pen to help orient the specimen to the defect[e2] (Fig. 150.7D)
• The layer is removed and placed on a transfer card or marked gauze while maintaining correct orientation relative to the defect (Fig. 150.7E)
• Hemostasis is obtained using electrocoagulation or thermocautery as indicated
• A sterile pressure dressing is placed on the wound and the patient is discharged to a waiting room while the tissue is processed

Handling of the tissue specimen
• A map of the specimen is drawn that is relative to anatomic landmarks including the skin notches (Fig. 150.7H) • The specimen is sectioned precisely in order to fit on the cryostat chuck and microscope slide (Fig. 150.7F) • Attention must be paid to maintaining proper numbering, inking and mapping of specimens • All cut margins, except the epidermal edge, are inked systematically with different colored dyes and recorded on the specimen map (Fig. 150.7G,H) • The technician prepares the tissue pieces for freezing by flattening them so that the epidermis lies in the same plane as the dermis and deep margins, using one of several available techniques; if any edge or portion of the specimen curves upward, relaxing cuts are placed on the top surface of the specimen • The technician embeds the tissue piece (deep surface upward) on a chuck with embedding medium and freezes it in the cryostat • Frozen sections are then cut, mounted on slides, and stained with hematoxylin and eosin (H&E)   • Toluidine blue stain can also be used because it is rapid and the purplish metachromatic stromal staining helps to distinguish BCCs from adnexal structures
Histopathologic assessment and additional layers
• The surgeon examines the frozen sections and marks any residual tumor foci on the specimen map (Fig. 150.7J) • If further resection is required, the surgeon precisely removes additional tissue in the area of residual tumor, using the map and skin notches present on the patient for orientation (Fig. 150.7K) • This process is repeated until all tissue margins are microscopically free of tumor • Once the tumor is completely removed, the final defect is measured and photographed and wound management options are discussed and implemented

Table 150.5 Mohs micrographic surgery (MMS) flow sheet. MSS requires a high-complexity approved laboratory, e.g. by CLIA (www.cms.gov/regulations-and-guidance/legislation/clia). Fig. 150.7 depicts the procedure. BCCs, basal cell carcinomas.

Downloaded for Anonymous User (n/a) at Egyptian Knowledge Bank from ClinicalKey.com by Elsevier on March 10, 2024. For personal use only. No other uses without permission. Copyright ©2024. Elsevier Inc. All rights reserved.

are required that cannot be performed reliably on frozen sections[97]. In addition, when there is histologic evidence of a second neoplasm or the histologic features of the tumor being removed via MMS and the preoperative diagnosis differ, the original FFPE sections should be reviewed.

Although infrequent, cutaneous neoplasms can invade bone. This may be the consequence of previous inadequate treatment, anatomic site (e.g. embryonic fusion planes, areas with thin overlying skin such as the scalp, sternum, and distal phalanx), tumor biology, and patient comorbidities (e.g. chronic lymphocytic leukemia, solid transplant-related immunosuppression). In addition, tumors with perineural invasion can gain access into bone via bony foramina. When tumors invade bone, the following strategies are used to control its growth and potentially effect a cure: (1) establish the diagnosis and mode of invasion of the tumor histologically; (2) obtain radiologic imaging to determine the macroscopic extent of bone involvement and status of the regional lymph nodes (see above); and (3) refer to a related subspecialist for bone

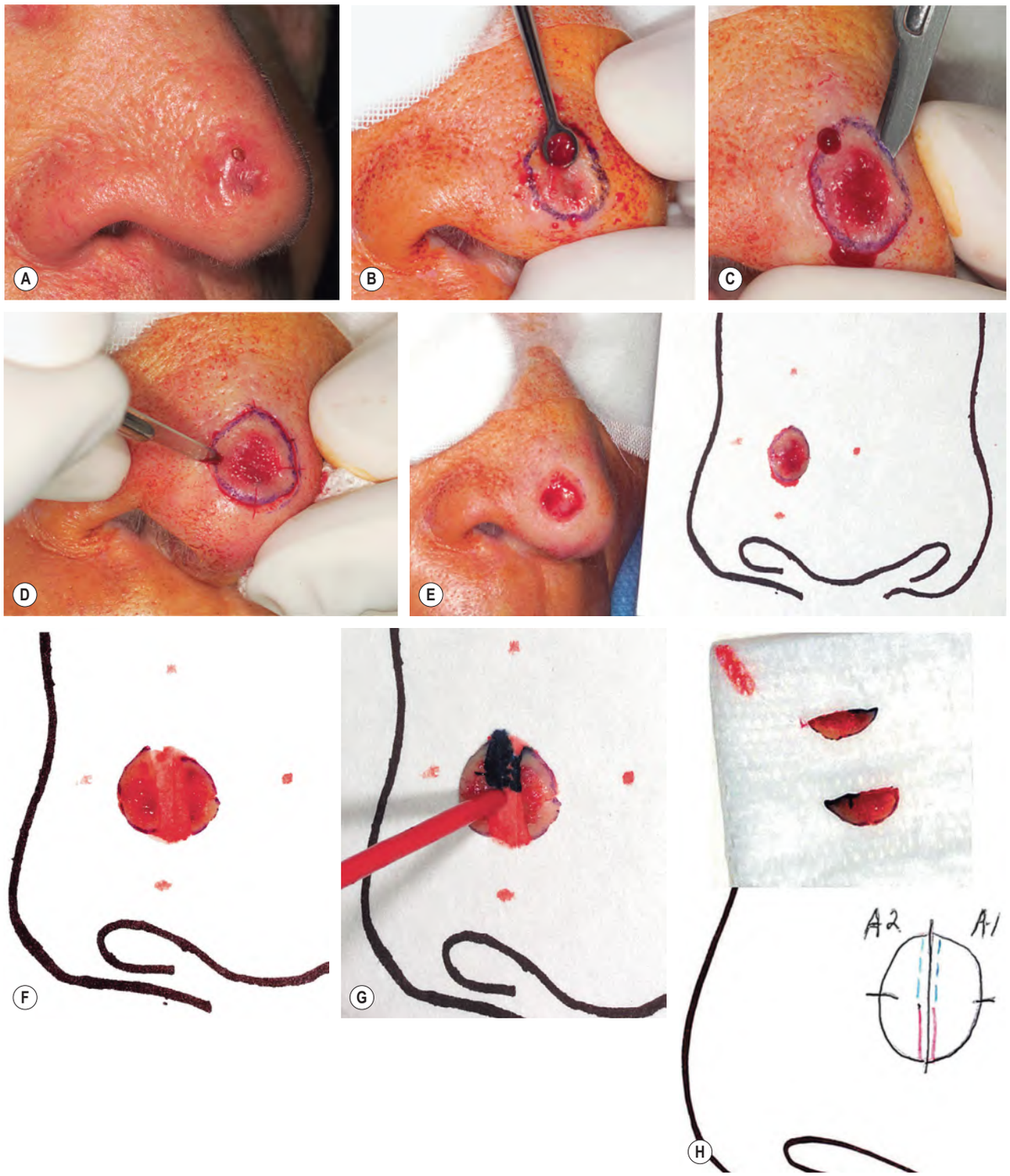

Fig. 150.7 Mohs micrographic surgery technique. A Preoperative appearance of a basal cell carcinoma on the nose. **B** Debulking of the tumor via curettage. **C** Beveled excision (with scalpel at a 45° angle) of all clinically evident tumor plus a small margin of normal-appearing skin. **D** Placement of skin notches at 3, 6, 9 and 12 o'clock positions in the specimen and adjacent surrounding tissue. **E** Orientation of the excised specimen on an anatomic card. **F** Specimen sectioned into two pieces and flattened. **G** Marking of the cut margins of the specimen with red and blue inks. **H** Matching Mohs map and tissue specimen ready for histologic preparation. A red mark on the gauze denotes the location of the first specimen with the second specimen always placed below. Different systems are used but precision is common to all.

Continued

Downloaded for Anonymous User (n/a) at Egyptian Knowledge Bank from ClinicalKey.com by Elsevier on March 10, 2024. For personal use only. No other uses without permission. Copyright ©2024. Elsevier Inc. All rights reserved.

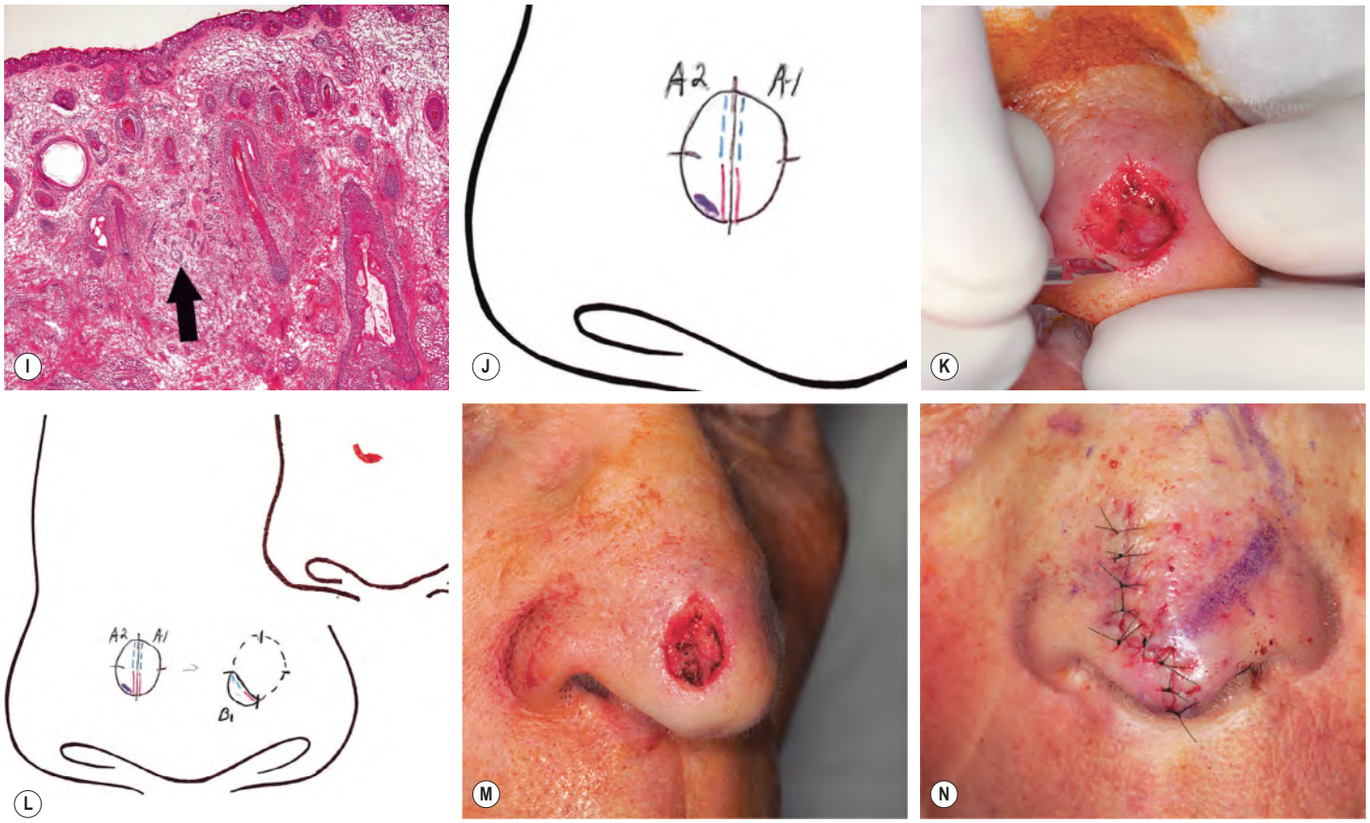

Fig. 150.7 Mohs micrographic surgery technique. (cont'd) **I** Histopathologic section with positive tumor denoted by the arrow. **J** Mohs map marked with purple at the site of cancer at the margin. **K** Re-excision of the area of residual basal cell carcinoma. **L** Mohs map from the second layer with corresponding tissue. **M, N** Postoperative tumor-free defect and repair. *Courtesy Clark C. Otley, MD, and Randall K. Roenigk, MD.*

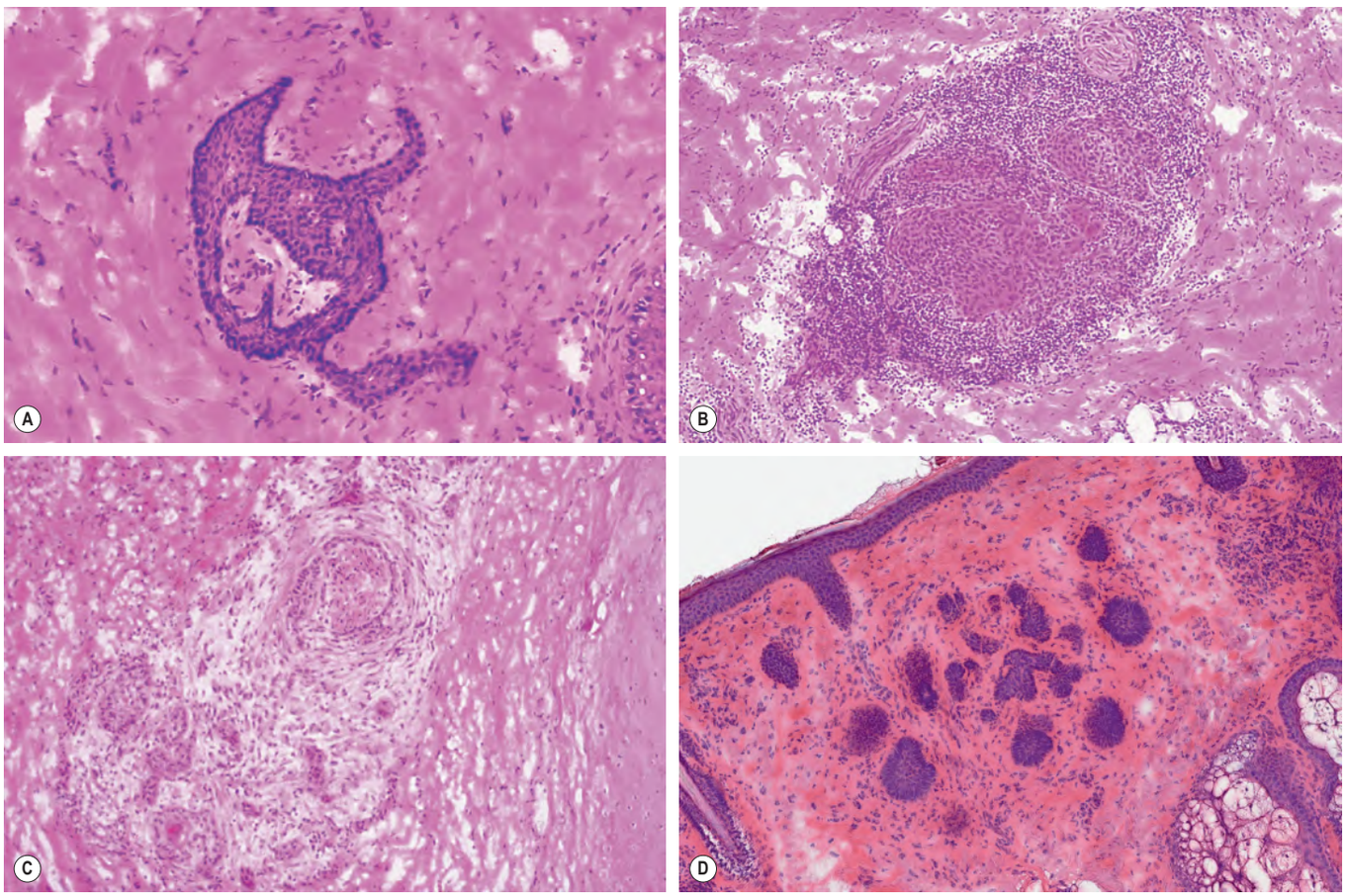

Fig. 150.8 Histopathologic challenges in Mohs surgery. A Folliculocentric basaloid proliferation may mimic basal cell carcinoma; however, the lack of clefting adjacent to the cells, apoptosis, or mitotic figures as well as the presence of a fibrous sheath permits distinction. **B** Dense inflammation can obscure tumor cells, as seen here with a squamous cell carcinoma in a patient with chronic lymphocytic leukemia. **C** Careful evaluation is required to identify subtle foci of perineural squamous cell carcinoma. **D** Follicular remnants can mimic basaloid islands. *A–C, Courtesy Clark C. Otley, MD, and Randall K. Roenigk, MD.*

Downloaded for Anonymous User (n/a) at Egyptian Knowledge Bank from ClinicalKey.com by Elsevier on March 10, 2024. For personal use only. No other uses without permission. Copyright ©2024. Elsevier Inc. All rights reserved.

resection as indicated. In difficult tumors with perineural invasion, additional Mohs layers may be taken to assure a tumor-free plane.

Small foci of sinus, nasal, or scalp bone may be excised locally with a bone rongeur or a chisel and mallet. Even when bone is exposed during tumor surgery, second intent healing is possible. If more than 1 cm of bone is exposed, burring, abrasion, or chiseling of spots 1 cm apart to reach bleeding spots can facilitate granulation. The procedure should be done with the patient recumbent to minimize the extremely rare risk of air embolus into the cavernous sinus (to date 2 cases reported). If sufficient granulation tissue can be stimulated to cover the exposed facial or scalp bone relatively quickly, cellulitis and osteomyelitis rarely occur[98]. Other options include coverage with an acellular dermal matrix or a split-thickness skin graft. These three methods of wound management are frequently preferred over more complex flaps that may delay detection of recurrent tumor. Close clinical surveillance is imperative.

RECONSTRUCTION

After complete tumor clearance, multiple options exist for management of tissue defects. The management strategy takes into account anatomic location, patient comorbidities, tumor severity, and the aesthetic needs of the patient. With guidance from the Mohs surgeon, patients are able to select the best options for reconstruction.

Surgical defects that heal by second intention may result in excellent cosmetic results especially in concave regions. Second intention healing can also be used for recurrent tumors in which flaps or grafts might hinder surveillance. Patients must be willing to attend to the area over a 2- to 8-week healing period. Typically, wound care regimens involve cleansing the wound daily with a saline solution or soapy water, applying a layer of ointment, and then covering with a non-adherent dressing. Wound care after cutaneous reconstruction is similar to second intention wound care, although limited to 1–2 weeks. A discussion of cutaneous reconstruction can be found in Chapters 146–148.

POSTOPERATIVE CARE

In addition to those given preoperatively (see Table 151.3), antibiotics may be given postoperatively for wound infection prophylaxis if surgery is extensive as well as for any debilitated patient for whom proper wound care is a concern[85]. Additionally, surgical reconstruction on highly sebaceous noses and distal lower extremities (below the knee) plus those near the nares and mouth may require prophylactic antibiotics. Pain control is assessed on a case-by-case basis. Substantial pain following MMS is uncommon. Acetaminophen is usually sufficient for postoperative discomfort, especially for smaller defects and simple repairs. Oral narcotic analgesics may be prescribed for patients with low pain thresholds, large tumors, complex reconstruction, or wounds in anatomic locations of high tension (e.g. scalp) or sensitivity (e.g. lip, nose, ear)[99]. One randomized controlled trial found the combination of acetaminophen and ibuprofen superior in controlling postoperative pain compared to acetaminophen with codeine and acetaminophen alone[99].

Ongoing surveillance at least annually for new primary and recurrent cancer is recommended for all patients, given that 50% of patients with keratinocyte carcinomas will experience another skin cancer during the subsequent 5 years.

COMPLICATIONS

Complications and adverse events from MMS are uncommon and the procedure has an undetectable mortality rate[100,101]. A large, multicenter, prospective cohort study of adverse events in MMS found that the rate of adverse events was <1%, with the majority being minor[100].

Intraoperative considerations include anxiety, pain (with local anesthesia injection), bleeding, nerve damage, and allergic reactions. If warranted, oral midazolam can be given in the range of 5–15 mg for healthy adults. Knowledge of vascular, muscular, and neural anatomy, especially within the "danger zones" of the face (see Ch. 142), helps to avoid and anticipate specific complications. Hemorrhage is a potential risk during surgery and is minimized with meticulous hemostasis and pressure bandaging. The superficial temporal artery is the most common major artery that may be transected, and its transection usually requires suture ligation. Epinephrine (adrenaline) included in the local anesthetic temporarily improves hemostasis. To date, there is no evidence that patients taking aspirin or warfarin for serious medical problems experience increased risks of serious hemorrhage or bleeding complications following MMS. In addition, while there is a significantly increased risk of bleeding complications in patients on thienopyridines (e.g. clopidogrel, ticlopidine) undergoing dermatologic surgery, these medications are typically continued due to the possible risk of internal thrombotic complications[102,103].

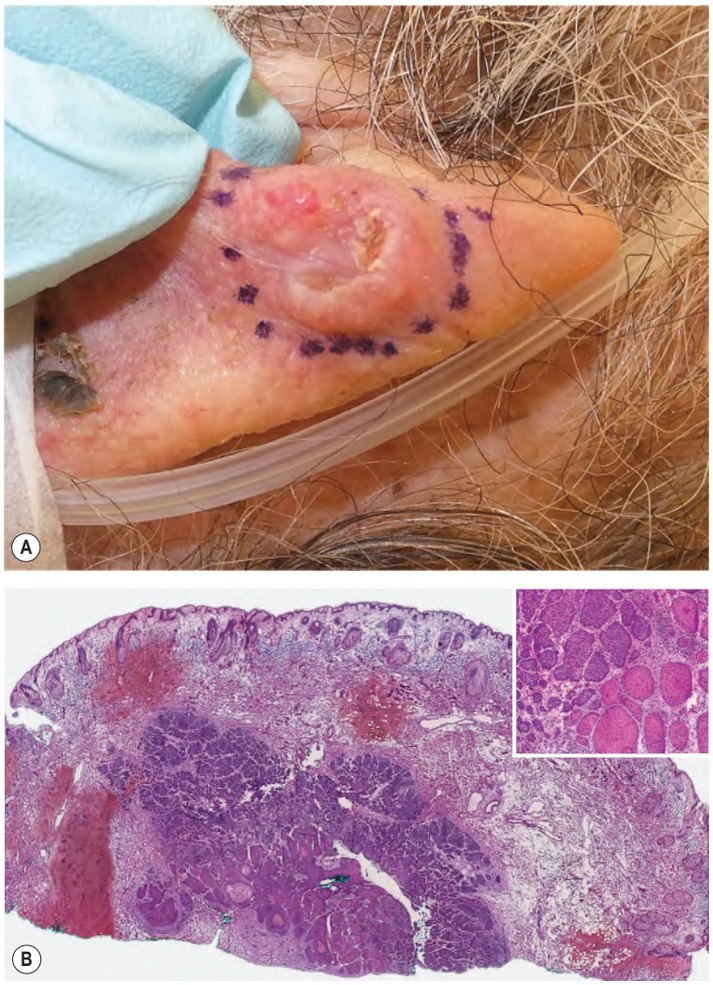

Fig. 150.9 Collision tumor – basal cell carcinoma (BCC) and squamous cell carcinoma (SCC). A A biopsy-proven micronodular/nodular BCC on the ear. **B** Frozen sections demonstrated distinct aggregates of uniform basaloid cells as well as variably large, irregular complexes of polygonal cells with eosinophilic cytoplasm and enlarged, partly pleomorphic nuclei (*inset*).

Injury to cutaneous sensory nerves occurs during all cutaneous surgery. Transection of significant motor nerves is occasionally necessary for removal of deeply invasive tumors, especially in the temporal region. Whenever possible, the surgeon should inform the patient before surgery of any possible loss of function or sensation.

Additional postoperative complications include infection, dehiscence, partial- or full-thickness necrosis, and seroma formation (see Ch. 151). Based upon several studies, the infection rate post MMS is very low (0.7%)[101,104,105].

FUTURE TRENDS

The history of MMS is one of continuous innovation and improvement. Potential enhancements include perioperative tumor definition via noninvasive imaging (e.g. reflectance confocal microscopy, optical coherence tomography) in order to visualize subclinical tumor involvement, use of rapid immunostains that enhance diagnostic sensitivity and specificity, new indications for MMS based upon evidence-based

Downloaded for Anonymous User (n/a) at Egyptian Knowledge Bank from ClinicalKey.com by Elsevier on March 10, 2024. For personal use only. No other uses without permission. Copyright ©2024. Elsevier Inc. All rights reserved.

medicine, and further refinements of practice guidelines centered on patient-related outcomes[1]. With the increase in the incidence of skin cancer, the demand for MMS will continue to rise. Given the risk of overuse of MMS, it is important to be mindful of its appropriate use, other viable treatment options, and shared decision-making with patients[1,5]. Current ongoing, large, multicenter database studies aim to further establish MMS as the treatment of choice for high-risk cutaneous neoplasms due to high cure rates, tissue sparing potential, safety, low complication rate, convenience of an outpatient procedure, and cost effectiveness[20,28–30,33].

Additional figures and table on Mohs Micrographic Surgery - Challenges, Pitfalls, and Recommendations available in our eBook (see inside front cover for access code).

REFERENCES

1. Connolly SM, Baker DR, Coldiron BM, et al. AAD/ACMS/ASDSA/ASMS 2012 appropriate use criteria for Mohs micrographic surgery: a report of the American Academy of Dermatology, American College of Mohs Surgery, American Society for Dermatologic Surgery Association, and the American Society for Mohs Surgery. *J Am Acad Dermatol*. 2012;67:531–550.
2. Mohs FE. Chemosurgery: A microscopically controlled method of cancer excision. *Arch Surg*. 1941;42:279–295.
3. Trost LB, Bailin PL. History of Mohs surgery. *Dermatol Clin*. 2011;29:135–139.
4. Tromovitch TA, Stegeman SJ. Microscopically controlled excision of skin tumors: chemosurgery (Mohs): fresh tissue technique. *Arch Dermatol*. 1974;110:231–232.
5. Hanke CW, Moy RL, Roenigk RK, et al. Current status of surgery in dermatology. *J Am Acad Dermatol*. 2013;69:972–1001.
6. Coldiron B. Commentary: Implementation of the appropriate-use criteria will not increase Mohs micrographic surgery utilization. *J Am Acad Dermatol*. 2014;71:36–37.
7. National Comprehensive Cancer Network. (www.nccn.org/guidelines/category_1).
8. Tierney EP, Hanke CW. Cost effectiveness of Mohs micrographic surgery: review of the literature. *J Drugs Dermatol*. 2009;8:914–922.
9. Seidler AM, Bramlette TB, Washington CV, et al. Mohs versus traditional surgical excision for facial and auricular nonmelanoma skin cancer: an analysis of cost-effectiveness. *Dermatol Surg*. 2009;35:1776–1787.
10. Rogers HW, Coldiron BM. Analysis of skin cancer treatment and costs in the United States Medicare population, 1996–2008. *Dermatol Surg*. 2013;39:35–42.
11. Cook J, Zitelli JA. Mohs micrographic surgery: a cost analysis. *J Am Acad Dermatol*. 1998;39:698–703.
12. Ravitskiy L, Brodland DG, Zitelli JA. Cost analysis: Mohs micrographic surgery. *Dermatol Surg*. 2012;38:585–594.
13. Rowe DE, Carroll RJ, Day Jr. CL. Long-term recurrence rates in previously untreated (primary) basal cell carcinoma: implications for patient follow-up. *J Dermatol Surg Oncol*. 1989;15:315–328.
14. Rowe DE, Carroll RJ, Day CL. Mohs surgery is the treatment of choice for recurrent (previously treated) basal cell carcinoma. *J Dermatol Surg Oncol*. 1989;15:424–431.
15. Roenigk RK, Roenigk HH. Current surgical management of skin cancer in dermatology. *J Dermatol Surg Oncol*. 1990;16:136–151.
16. Chren M, Linos E, Torres JS, et al. Tumor recurrence 5 years after treatment of cutaneous basal cell carcinoma and squamous cell carcinoma. *J Invest Dermatol*. 2013;133:1188–1196.
17. Mikhail GR. Cancers, precancers, and pseudocancers on the male genitalia. A review of clinical appearances, histopathology, and management. *J Dermatol Surg Oncol*. 1980;6:1027–1035.
18. Kwiek B, Schwartz RA. Keratoacanthoma (KA): An update and review. *J Am Acad Dermatol*. 2016;74:1220–1233.
19. Bricca GM, Brodland DG, Ren D, Zitelli JA. Cutaneous head and neck melanoma treated with Mohs micrographic surgery. *J Am Acad Dermatol*. 2005;52:92–100.
20. Bene NI, Healy C, Coldiron BM. Mohs micrographic surgery is accurate 95.1% of the time for melanoma in situ: a prospective study of 167 cases. *Dermatol Surg*. 2008;34:660–664.
21. Valentín-Nogueras SM, Brodland DG, Zitelli JA, et al. Mohs micrographic surgery using MART-1 immunostain in the treatment of invasive melanoma and melanoma in situ. *Dermatol Surg*. 2016;42:733–744.
22. Etzkorn JR, Sobanko JF, Elenitsas R, et al. Low recurrence rates for in situ and invasive melanomas using Mohs micrographic surgery with melanoma antigen recognized by T cells 1 (MART-1) immunostaining: tissue processing methodology to optimize pathologic staging and margin assessment. *J Am Acad Dermatol*. 2015;72:840–850.
23. Newman J, Beal M, Schram SE, Lee PK. Mohs micrographic surgery for lentigo maligna and lentigo maligna melanoma using Mel-5 immunostaining: an update from the University of Minnesota. *Dermatol Surg*. 2013;39:1794–1799.
24. Nosrati A, Berliner JG, Goel S, et al. Outcomes of melanoma in situ treated with mohs micrographic surgery compared with wide local excision. *JAMA Dermatol*. 2017;153:436–441.
25. Tolkachjov SN, Kelley BF, Aladhdab F, et al. Atypical fibroxanthoma: systemic review and meta-analysis of treatment with Mohs micrographic surgery or excision. *J Am Acad Dermatol*. 2018;79:929–934.
26. Lowe GC, Onajin O, Baum CL, et al. A comparison of Mohs micrographic surgery and wide local excision for treatment of dermatofibrosarcoma protuberans with long-term follow-up: the Mayo Clinic experience. *Dermatol Surg*. 2017;43:98–106.
27. Ratner D, Thomas CO, Johnson TM, et al. Mohs micrographic surgery for the treatment of dermatofibrosarcoma protuberans. Results of a multiinstitutional series with an analysis of the extent of microscopic spread. *J Am Acad Dermatol*. 1997;37:600–613.
28. Gloster HM, Harris KR, Roenigk RK. A comparison between Mohs micrographic surgery and wide surgical excision for the treatment of dermatofibrosarcoma protuberans. *J Am Acad Dermatol*. 1996;35:82–87.
29. Snow SN, Gordon EM, Larson PO, et al. Dermatofibrosarcoma protuberans: a report on 29 patients treated by Mohs micrographic surgery with long-term follow-up and review of the literature. *Cancer*. 2004;101:28–38.
30. Boyer JD, Zitelli JA, Brodland DG, D'Angelo G. Local control of primary Merkel cell carcinoma: review of 45 cases treated with Mohs micrographic surgery with and without adjuvant radiation. *J Am Acad Dermatol*. 2002;47:885–892.
31. Leibovitch I, Huilgol SC, Selva D, et al. Microcystic adnexal carcinoma: treatment with Mohs micrographic surgery. *J Am Acad Dermatol*. 2005;52:295–300.
32. Chiller K, Passaro D, Scheuller M, et al. Microcystic adnexal carcinoma: forty-eight cases, their treatment, and their outcome. *Arch Dermatol*. 2000;136:1355–1359.
33. Snow S, Madjar DD, Hardy S, et al. Microcystic adnexal carcinoma: report of 13 cases and review of the literature. *Dermatol Surg*. 2001;27:401–408.
34. Spencer JM, Nossa R, Tse DT, Sequeira M. Sebaceous carcinoma of the eyelid treated with Mohs micrographic surgery. *J Am Acad Dermatol*. 2001;44:1004–1009.
35. O'Connor WJ, Lim KK, Zalla MJ, et al. Comparison of Mohs micrographic surgery and wide excision for extramammary Paget's disease. *Dermatol Surg*. 2003;29:723–727.
36. Damavandy AA, Terushkin V, Zitelli JA, et al. Intraoperative immunostaining for cytokeratin-7 during Mohs micrographic surgery demonstrates low local recurrence rates in extramammary Paget's disease. *Dermatol Surg*. 2018;44:354–364.
37. Humphreys TR, Finkelstein DH, Lee JB. Superficial leiomyosarcoma treated with Mohs micrographic surgery. *Dermatol Surg*. 2004;30:108–112.
38. Leibovitch I, Huilgol SC, Selva D, et al. Basosquamous carcinoma: treatment with Mohs micrographic surgery. *Cancer*. 2005;104:170–175.
39. Paoli J, Daryoni D, Wennberg AM, et al. 5-year recurrence rates of Mohs micrographic surgery for aggressive and recurrent facial basal cell carcinoma. *Acta Derm Venereol*. 2011;91:689–693.
40. Ratner D, Lowe L, Johnson TM, Fader DJ. Perineural spread of basal cell carcinomas treated with Mohs micrographic surgery. *Cancer*. 2000;88:1605–1613.
41. Leibovitch I, Huilgol SC, Selva D, et al. Cutaneous squamous carcinoma in situ (Bowen's disease): treatment with Mohs micrographic surgery. *J Am Acad Dermatol*. 2005;52:253–260.
42. Holmkvist KA, Roenigk RK. Squamous cell carcinoma of the lip treated with Mohs micrographic surgery: outcome at 5 years. *J Am Acad Dermatol*. 1998;38:960–966.
43. Zaiac MN, Weiss E. Mohs micrographic surgery of the nail unit and squamous cell carcinoma. *Dermatol Surg*. 2001;27:246–251.
44. Coit DG, Thompson JA, Albertini MR, et al. Cutaneous Melanoma, Version 2.2019, NCCN Clinical Practice Guidelines in Oncology. *J Natl Compr Canc Netw*. 2019;17:367–402.
45. Beaulieu D, Fathi R, Srivastava D, et al. Current perspectives on Mohs micrographic surgery for melanoma. *Clin Cosmet Investig Dermatol*. 2018;11:309–320.
46. Lee MP, Sobanko JF, Shin TM, et al. Evolution of Excisional Surgery Practices for Melanoma in the United States. *JAMA Dermatol*. 2019;155:1244–1251.
47. Connolly KL, Nehal KS, Busam KJ. Lentigo maligna and lentigo maligna melanoma: contemporary issues in diagnosis and management. *Melanoma Manag*. 2015;2:171–178.
48. Bene NI, Healy C, Coldiron BM. Mohs micrographic surgery is accurate 95.1% of the time for melanoma in situ: a prospective study of 167 cases. *Dermatol Surg*. 2008;34:660–664.
49. Albertini JG, Elston DM, Libow LF, et al. Mohs micrographic surgery for melanoma: a case series, a comparative study of immunostains, an informative case report, and a unique mapping technique. *Dermatol Surg*. 2002;28:656–665.
50. Cohen LM, McCall MW, Zax RH. Mohs micrographic surgery for lentigo maligna and lentigo maligna melanoma. A follow-up study. *Dermatol Surg*. 1998;24:673–677.
51. Kim J, Taube JM, McCalmont TH, et al. Quantitative comparison of MiTF, Melan-A, HMB-45 and Mel-5 in solar lentigines and melanoma in situ. *J Cutan Pathol*. 2011;38:775–779.
52. Christensen KN, Hochwalt PC, Hocker TL, et al. Comparison of MITF and Melan-A immunohistochemistry during Mohs surgery for lentigo maligna-type melanoma *in situ* and lentigo maligna melanoma. *Dermatol Surg*. 2016;42:167–175.
53. Trimble JS, Cherpelis BS. Rapid immunostaining in Mohs: current applications and attitudes. *Dermatol Surg*. 2013;39:56–63.
54. Swetter SM, Tsao H, Bichakjian CK, et al. Guidelines of care for the management of primary cutaneous melanoma. *J Am Acad Dermatol*. 2019;80:208–250.
55. Bricca GM, Brodland DG, Ren D, Zitelli JA. Cutaneous head and neck melanoma treated with Mohs micrographic surgery. *J Am Acad Dermatol*. 2005;52:92–100.
56. Cheraghlou S, Christensen SR, Agogo GO, Girardi M. Comparison of survival after Mohs micrographic surgery vs wide margin excision for early-stage invasive melanoma. *JAMA Dermatol*. 2019;155:1252–1259.
57. Zalla MJ, Lim KK, Dicaudo DJ, Gagnot MM. Mohs micrographic excision of melanoma using immunostains. *Dermatol Surg*. 2000;26:771–784.
58. Bub JL, Berg D, Slee A, Odland PB. Management of lentigo maligna and lentigo maligna melanoma with staged excision: a 5-year follow-up. *Arch Dermatol*. 2004;140:552–558.
59. Johnson TM, Headington JT, Baker SR, Lowe L. Usefulness of the staged excision for lentigo maligna and lentigo maligna melanoma: the "square" procedure. *J Am Acad Dermatol*. 1997;37:758–764.
60. Abdelmalek M, Loosemore MP, Hurt MA, Hruza G. Geometric staged excision for the treatment of lentigo maligna and lentigo maligna melanoma: a long-term experience with literature review. *Arch Dermatol*. 2012;148:599–604.
61. Gaudy-Marqueste C, Perchenet AS, Tasei AM, et al. The "spaghetti technique": an alternative to Mohs surgery or staged surgery for problematic lentiginous melanoma (lentigo maligna and acral lentiginous melanoma). *J Am Acad Dermatol*. 2011;64:113–118.
62. Moyer JS, Rudy S, Boonstra PS, et al. Efficacy of staged excision with permanent section margin control for cutaneous head and neck melanoma. *JAMA Dermatol*. 2017;153:282–288.
63. Whalen J, Leone D. Mohs micrographic surgery for the treatment of malignant melanoma. *Clin Dermatol*. 2009;27:597–602.
64. Trotter MJ. Melanoma margin assessment. *Clin Lab Med*. 2011;31:289–300.

Downloaded for Anonymous User (n/a) at Egyptian Knowledge Bank from ClinicalKey.com by Elsevier on March 10, 2024. For personal use only. No other uses without permission. Copyright ©2024. Elsevier Inc. All rights reserved.